CASE REPORT

Endometrial osseous metaplasia: Clinicopathological study.

Mukesh Mittal*, Pankaj Kumar Nitharwal, Mukesh Bijarniya***, Batti Lal Meena****, Vaishali Singh*****

ABSTRACT

Osseous metaplasia of the endometrium is an uncommon disorder associated with the presence of bone in the uterine endometrium. Most of the cases present with secondary infertility after an abortion. We report a case of a 21-year-old woman who presented with intermittent bleeding per vagina due to osseous metaplasia in the endometrial cavity. Multiple theories have been proposed and the most accepted theory is metaplasia of the stromal cells into osteoblastic cells that produce the bone. Removal of these bony parts from endometrium leads to normal menstrual cycle.

INTRODUCTION

Osseous metaplasia of the endometrium is a rare pathology in which abnormal bone formation occurs in the endometrium. In most of the cases, ossification was followed by an abortion and patient presented with infertility. Patient may also present with symptoms such as menstrual abnormalities, dysmenorrhea, pelvic pain and abnormal vaginal discharge. The bone in the endometrial lining acts as an intrauterine device and it can be a cause of infertility. Hysteroscopic removal of the bony fragments usually results in resolution of most symptoms and return of fertility.

CASE PRESENTATION

A 23-year-old female patient presented to gynecology OPD department with the history of intermittent bleeding per vagina, dysmenorrhea and lower abdominal pain since 2 months with H/O normal vaginal delivery before 8 months.

Trans-abdominal USG revealed an echogenic area in the uterine cavity measuring 19 x 6 mm with distal acoustic shadow without any vascularity suggestive of calcification (figure 1). On the basis of the imaging findings and clinical history, the presumptive diagnosis was endometrial osseous metaplasia which was confirmed by histopathology.

The hematoxylin and eosin stained paraffin sections showed trabeculae intermingled with endometrial tissue. Retained products of conception, inflammatory reaction and necrosis were absent. No evidence of granuloma was seen (figure 2).

The osseous fragments were removed with the help of graspers of a rigid hysteroscope. Since the fragments were not deeply embedded, hysteroscopic resection was not necessary in this patient.

Postoperative sonography revealed a normal endometrial lining and on histopathology diagnosis of osseous metaplasia of the endometrium was confirmed.

DISCUSSION

Ossification of the endometrium is a rare clinical entity. It has many synonyms such as endometrial ossification, ectopic intrauterine bone, and heterotopic intrauterine bone. In most of the reported cases, the osseous changes in the endometrium were followed by a previous history of abortion[1]. Majority of the patients are in the reproductive age group with history of first trimester abortion either therapeutic or spontaneous and have normal vaginal delivery. The time interval between the antecedent abortion /vaginal delivery and discovery of endometrial ossification varies from 8 weeks to years in reproductive age group[2].

Common clinical presentations are menstrual irregularities, pelvic pain, dysmenorrhea, vaginal discharge, and secondary infertility. Endometrial ossification is described as an endogenous non-neoplastic pathological condition without tissue reaction in the endometrial tissue and the endometrium showed normal

*Professor, Department of Radiodiagnosis, SMS Medical College, Jaipur,
**Assistant Professor, Department of Radiodiagnosis, SMS Medical College, Jaipur
***Junior Resident, Department of Radiodiagnosis, SMS Medical College, Jaipur
****Assistant Professor, Department of Pathology, SMS Medical College, Jaipur

Corresponding Author:
Dr. Pankaj Kumar Nitharwal, Assistant Professor, Department of Radiodiagnosis, SMS Medical College, Jaipur
Mobile: 8447445938
Mail ID: pankaj6468@gmail.com

regular cyclical changes with presence of osseous trabeculae[2].

The pathogenesis of this rare condition is still disputed. The two most accepted mechanisms involve either the presence of chronic endometriosis with undifferentiated mesenchymal cells inducing the endometrial stromal cells transformation into osteoblast, or miscarriage with dystrophic ossification of the residual product of conception[2,3].

Infertility is caused by the action of these osseous trabeculae similar to the action of an intrauterine contraceptive device (IUCD). Infertility and endometrial calcification and subsequent ossification can be caused by endometrial tuberculosis in India[4].

Previously treatment of this ossification of the endometrium was a series of dilatation and curettage to remove the bony trabeculae from the endometrium. Vigorous single curettage can further lead to formation of synechiae[2]. Ultrasonic guided hysteroscopic removal of these osseous trabeculae helps proper visualizations and complete removal of the bony spicules that may be embedded in the myometrium[1].

REFERENCES

1. Magudapathi C, Anathakrishnan R, Kalargala H. Osseous Metaplasia of the Endometrium: A Rare Entity. J ObstetGynaecol India. 2015 Oct;65(5):342-5.
2. Umashankar T, Patted S, Handigund R. Endometrial osseous metaplasia: Clinicopathological study of a case and literature review. J Hum Reprod Sci. 2010 May;3(2):102-4.
3. Cayuela E, Perez-Medina T, Vilanova J, Alejo M, Cañadas P. True osseous metaplasia of the endometrium: the bone is not from a fetus. Fertility and sterility. 2009 Apr 1;91(4):1293-e1.
4. Patil S, Narchal S, Paricharak D, More S. Endometrial osseous metaplasia: case report with literature review. Ann Med Health Sci Res. 2013 Nov;3(Suppl 1):S10-2.

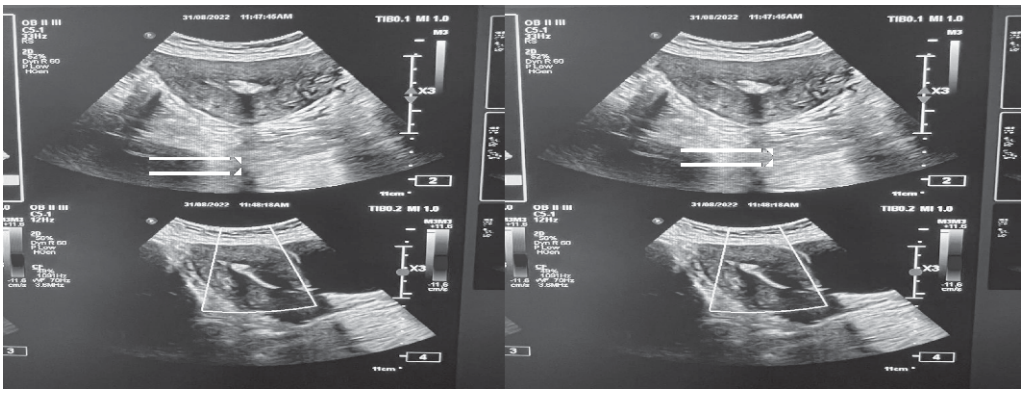

Figure 1 Trans-abdominal ultrasound showing linear calcifications in the uterine cavity



Figure 2. Photomicrography with low and medium magnification showing osseous trabecula